

Advantages of Utilizing Freeze Dried Collagen Sheets in Non-Surgical “Mesolift” of the Neck and Face

Joseph F. Greco, PhD, PA/C

Summary

The use of 100% natural freeze dried collagen sheets may be an effective adjunctive treatment to increase skin toning and tightening when utilized with lipolytic and skin toning injections in non-surgical neck and face lifting, Mesolift. The obvious advantages include (1) a decrease in post treatment bruising, (2) a decrease in swelling (3) decrease in puritis (4) an increase in tissue hydration (4) and an increase in patient comfort, acceptance and satisfaction.

Introduction

There is extensive literature on the effectiveness collagen plays in wound healing, especially with first and second degree burns, as well as its usefulness to enhance granulation in leg ulcers (1).

This author has previously used natural freeze dried collagen sheets in hair restoration surgery. (2) The collagen sheets are applied to the recipient site for 20 mins post- operatively and when the sheets are removed the recipient area is completely void of clots and well hydrated. There is a remarkable improvement in hemostasis when the collagen sheets are applied post operative in hair restoration procedures compared to patients without the collagen sheets.

“Native” Collagen Fiber (“Native” meaning “no heat, chemicals or solvents” and it has the same properties as live Collagen) needs no preservatives because no germs grow in its dry state, and because the material is discarded after use. It has maximum water-binding action as compared to standard denatured collagen. When moistened, the mask turns into a gel-like material which can easily be molded onto the skin. It is basically a reproduction of skin’s actual connective tissue structure, and is often referred to as “second skin”.

Collagen sheets are 100% pure native bovine collagen immersed in the finest-grade soluble collagen and freeze-dried to form a velvet-like tissue (8 1/2 x 11), which can be cut into strips. Immediate visible results include: diminishes fine lines; expression lines from nose to mouth are smoothed; puffiness under the eyes and discoloration are minimized; Skin is hydrated and firm after treatment.

Native collagen as humectants can absorb 30 times its fiber weight in water. (Native means no heat, chemicals or solvents and it has the same properties as live collagen) Because natural collagen is utilized it is able to deliver protein into the skin unlike competing synthetic collagen masks.

Fig # 1 illustrates the collagen sheets applied immediately after her mesolift injections.

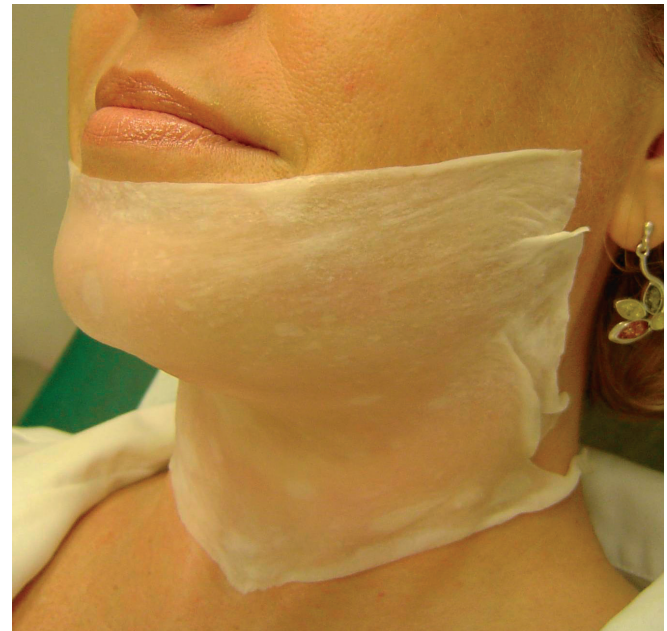

Fig 1

Notice the swelling and erythema Fig #2 in the areas of the injections.

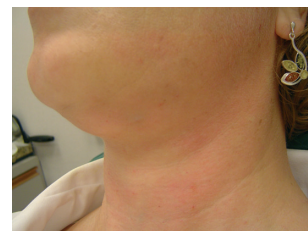

Fig 2

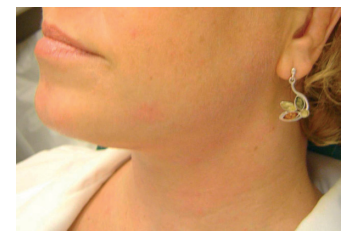

Fig 3

Notice the decrease in erythema and edema in Fig #3 after removal of the collagen.

“Collagen and collagen properties have been shown to have a pronounced effect on hemostasis. Hemostasis is the first step of any wound healing process and data available clearly indicates that collagen interacts with platelets to initiate the first step of the process, hemostasis”. (3)

“It has been reported that collagen attracts fibroblasts in cell culture and causes directed migration of cells”. (4, 5, 6) A significant increase in the production of fibroblasts was reported by Gogia when collagen sponge dressings were used with hyaluronic acid and the hemostasis is followed by vasoconstriction and vasodilatation. (7)

“Platelets not only initiate hemostasis, but they also release a number of biologically active substances including extra cellular matrix molecules, such as fibronectin, fibrinogen, and some growth factors, such as platelet derived growth factor.”(9) Additionally, this healthy “immune response” sending growth factors to the treated area secondary to the injections which tightens and remodels the skin by increasing the collagen and elastin. See Fig 4,5,6,7.

Mesotherapy, a minimally invasive procedure widely used in Europe, that utilizes micro injections of conventional FDA approved medicines, homeopathic, vitamins, minerals and amino acids into the mesoderm “middle layer of skin” to achieve a desired result. It is the synergistic effect of the formulas, the bodies “immune response” caused by the needles, which produce the desired effect. Cosmetic mesotherapy is used primarily to dissolve fat, tighten and tone skin and reduce cellulite.

Fig 4 below is a Mesolift of the neck and face before and Fig 5 is the Mesolift after. This patient had four Mesotherapy treatments followed by the collagen treatments three weeks apart. Note the reduction of fat in the neck and jowls, as well as, the tightening of the jaw line and the face.

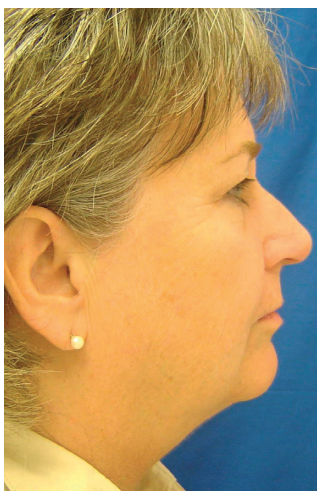

Fig 4

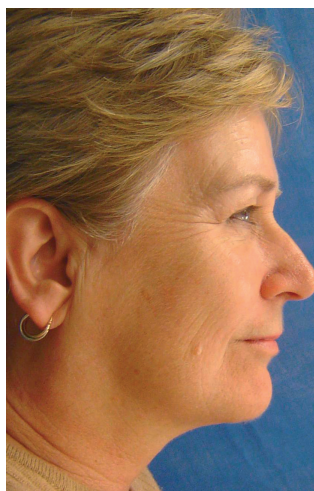

Fig 5

The after result in Fig 5 is obviously a synergistic effect of the lypolitic injections, the skin toning injections, the patient’s own immune response and the collagen treatments. This patient looks as though she has lost weight in her face when, in fact, she had no weight reduction.

Fig 6 is a third patient before three Mesolift procedures of the neck and face to reduce fat, tone skin followed by the collagen treatments.

Fig 7 is the patient after her treatments. Note the tightening of the jowl area and the lifting of the neck and jaw line in Fig 7.

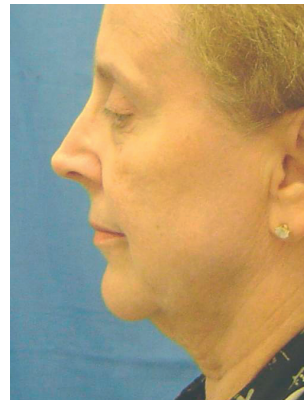

Fig 6

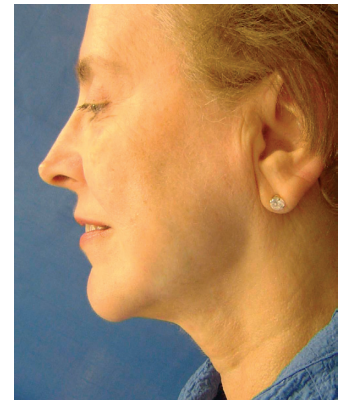


Fig 7

While collagen based dressings do not play one specific role in wound healing, they provide a suitable healing environment at each stage. In addition to the positive results in seen in hair restoration, wound care and Mesolift treatments, further studies are under way to investigate the positive effect the collagen sheets may have after laser skin resurfacing, chemical peels and dermabrasion.

The freeze dried collagen sheets are supplied by Reviva Labs, Haddonfield, New Jersey. Contact revivalabs.com. The author has no financial interest with Reviva Labs.

References

1. Burton, J. L. Etherington, D. J., and Peachey, B. D. 0. (1978). *Br. J. Dermatol* 99, 681.
2. Greco, J, Third Congress Italian Hair Restoration Society, Rome, Italy, Presentation, June 6th 1997.
3. Albritton, J.S.; *Clinics in Podiatric Medicine and Surgery*, 8(4), 1991, 773-785
4. Dunn, GA., Ebendal, T., *Exp. Cell Res.* 1978, 111, 475-479
5. Grinnell, F., Bennett, M.H., *Meth. Enz.* 1982,82, 535-544
6. Thomaseck, J.T., Hay, E.D., Fujiware, K., *Dev. Biol.* 1982, 92, 107-122
7. Gogia, P.P, *Ostomy/Wound Management*, 38(9), 1992, 13-20.
8. Clark, Richard A.F., *Arch Dermatol*, Volume 124, February 1988.